

Report

Hydroquinone-induced exogenous ochronosis: a report of four cases and usefulness of dermoscopy

Raúl Charlín, MD, Carlos B. Barcaui, MD, MS, PhD, Bernard Kawa Kac, MD, Deborah Brazuna Soares, MD, Rosa Rabello-Fonseca, MD, and Luna Azulay-Abulafia, MD, MS, PhD

From the Instituto de Dermatologia Professor R. D. Azulay, Hospital Santa Casa da Misericórdia do Rio de Janeiro, Brazil

Correspondence

Raúl Charlín Fernández
Los Navegantes 2179 Depto B, Providencia
Santiago
Chile
E-mail: rauliano@hotmail.com

Abstract

Hydroquinone is the first choice of topical bleaching agents used in treatment of melasma. In Brazil, hydroquinone is widely prescribed by physicians and often used by patients without a prescription. The principal adverse effects of its chronic use are confetti-like depigmentation and exogenous ochronosis. The latter manifests clinically with gray-brown or blue-black hyperpigmentation, as well as pinpoint hyperchromic papules that look like caviar, and therefore called caviar-like. On histopathology, curved ochre-colored structures, 'banana-shaped' fibers, appear in the papillary dermis. No description of dermoscopy in ochronosis is found in the literature. We report four cases of hydroquinone-induced exogenous ochronosis. Dermoscopy was performed in two patients on the areas with ochronosis, and in addition to the melasma findings, amorphous densely pigmented structures obliterating some follicular openings were observed. Exogenous ochronosis is an avoidable dermatosis that is difficult to treat. Dermatologists should be able to differentiate it from melasma and immediately discontinue hydroquinone. Dermoscopy might become a valuable resource in approaching exogenous ochronosis.

Introduction

The term *ochronosis* was coined by Virchow¹ in 1866 and refers to the brownish-yellow or ochre-colored accumulations of pigment found in the connective tissue of patients with the disease. There are two types of ochronosis: endogenous and exogenous.

Endogenous ochronosis or alkaptonuria is an autosomal recessive disease² caused by a deficiency of the enzyme homogentisic oxidase, which oxidizes homogentisic acid, a metabolite of tyrosine and phenylalanine. The deficiency of this enzyme leads to an accumulation of homogentisic acid in the connective tissues, which polymerizes to form ochre-colored pigment deposits in the dermis, cartilage, and tendons³. Clinically, endogenous ochronosis presents with a triad of dark urine (in contact with air or an alkali), cutaneous hyperpigmentation, and arthropathy. Thickening of the cartilage of the pinnae and dark cerumen are also characteristic. There is a visible hyperpigmentation principally of the sclerae, axillae, inguinal regions, and joints.^{4,5}

In 1912, Beddard and Plumtre⁶ for the first time described exogenous ochronosis in a patient that used phenol on a leg ulcer.

Exogenous ochronosis can be secondary to the topical application of hydroquinone, phenol,⁶⁻⁸ resorcinol,^{2,9} or oral administration of antimalarials.¹⁰⁻¹⁴ Ochronosis secondary to hydroquinone was first described in 1975 by Findlay⁹ in

patients who regularly applied this topical bleaching agent. It occurs almost exclusively in patients with a high phototype¹⁵ (Fitzpatrick's classification¹⁶). Ochronosis is due to the continual and chronic use of the hydroquinone, not necessarily in high concentrations. Ochronosis resulting from the use of 2% hydroquinone has been described.¹⁷

There are various theories that explain exogenous ochronosis. The most accepted is that of Penneys¹⁸ who attributed the hyperpigmentation to the inhibition of the enzyme homogentisic oxidase by hydroquinone. This inhibition leads, like in endogenous ochronosis, to the accumulation of homogentisic acid that polymerizes to form ochre pigment in the papillary dermis.

Exogenous ochronosis manifests as hyperpigmentation in photo-exposed regions.¹⁹ It occurs over osseous surfaces²⁰ often affecting the zygomatic^{15,21} regions in a symmetrical pattern. The lesions are gray-brown or blue-black macules²² usually with hyperchromic, pinpoint, caviar-like papules.^{9,20}

In 1979, the South African author Dogliotte²³ classified exogenous ochronosis into three clinical stages: (i) erythema and mild hyperpigmentation; (ii) hyperpigmentation, pigmented colloid milium (caviar-like lesions) and scanty atrophy; and (iii) papulo-nodular lesions.

The histopathology of ochronosis lesions is characterized by pigment incontinence, solar elastosis, and brownish-yellow (ochre), 'banana-shaped' fibers, in the papillary

dermis, and eventually degeneration of the collagen.^{2,9,22,23} Occasionally, colloid milium^{9,22} and/or granulomas¹ are detected.

It is not difficult to differentiate ochronosis and melasma on histopathologic basis. The latter show a significant increase in the amount of melanin in all epidermal layers seen in Fontana-Masson. It is controversial whether melanocytes are increase in number in melasma. Sanchez²⁴ *et al.* and Kang²⁵ *et al.* reported an increase in the number of melanocytes in melasma. Recently, Grimes²⁶ *et al.* were not able to confirm the quantitative increase in the number of epidermal melanocytes. Pigment incontinence and melanophages might be present either in melasma²⁷ and ochronosis. Solar elastosis is seen both in melasma²⁵ and in ochronosis. In fact, ochronosis is usually superimposed on the skin affected by melasma. There are no ochre fibers in melasma, the characteristic finding in ochronosis.

Various treatments have been used for exogenous ochronosis, usually with frustrating results.²⁸ Satisfactory results have been described with retinoic acid,^{29,30} dermabrasion,^{31,32} cryotherapy,²¹ CO₂ laser,¹⁵ Q-switched ruby laser,^{33,34} Q-switched alexandrine 755 laser,²² among others.

We report four patients with exogenous ochronosis, all classified as Dogliotte stage 2. All had used hydroquinone over an extended period of time for melasma treatment, in concentrations up to 6%.

Case Reports

Case 1

A 56-year-old woman (a teacher), phototype IV, presented with a history of long-term facial melasma, treated with 2–4% hydroquinone creams for 20 years. She complained of progressive worsening of the hyperpigmentation in the zygomatic region in the last years. No other oral or topical medications were used by the patient. On dermatologic examination, she had hyperchromic, gray-brown macules, speckled with pinpoint, dark brown (caviar-like) papules in the zygomatic and infraorbital regions (Fig. 1). A brown macule on the dorsal of the nose was also observed. It was classified as stage 2 Dogliotte.

Case 2

A 44-year-old woman (a housewife), phototype IV, presented with a history of facial melasma over 10 years, starting with her last pregnancy. She was treated with 2–5% hydroquinone during this time, with initial improvement, but now presented with progressive darkening. She reported the occasional use of metamizole (dipyrone). On physical examination, she had bilateral blue-brown macules on the malar, submalar, and temporal regions, and blue-black pinpoint papules (caviar-like lesions) dispersed over the macules. She also had light brown macules on the frontal region, upper lip, and chin. It was classified as stage 2 Dogliotte.

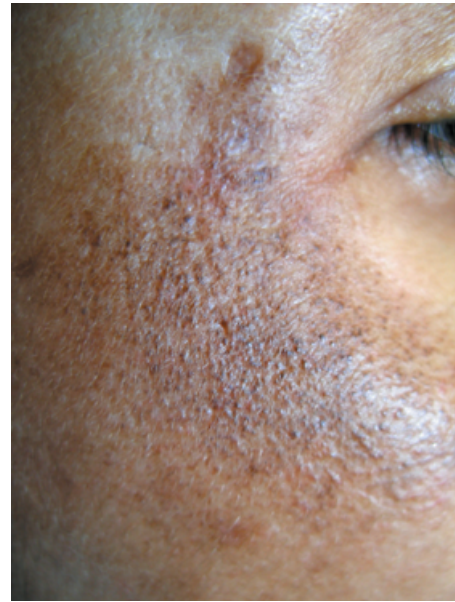


Figure 1 Gray-brown macules in the zygomatic region, spotted with pinpoint, dark brown (caviar-like) papules

Case 3

A 56-year-old woman (a teacher), phototype V, with 25 years of melasma, treated with up to 6% hydroquinone, sought medical care for worsening of the hyperpigmentation. She denied use of any other medication. On physical examination, she had a gray-brown pigmentation on the entire face, except for the upper lip and frontal regions. In addition, there were papules of the same color, or slightly more hyperchromic, of 2–3 mm in diameter, inside the borders of the hyperpigmentation. Confetti-like depigmentation was observed on the cheeks. It was classified as stage 2 Dogliotte.

Case 4

A 51-year-old woman (an ambulatory vendor), phototype V, with 10 years of up to 5% hydroquinone use, presented for treatment of melasma. She observed worsening of the hyperpigmentation in recent years. She used no other medications. On dermatologic examination, bilateral brown macules, with confetti-like depigmentation within the borders of the lesion, were observed on the cheeks. She also presented with darker, gray-brown areas, with caviar-like pinpoint papules in the zygomatic region (Fig. 2). It was classified as stage 2 Dogliotte.

No patient complained of arthralgia nor presented with altered urine color, hyperpigmentation of the sclerae, joints, axillae, or genitals. There was also no thickening of the pinnae or dark cerumen.

Cutaneous biopsies from all patients were taken from the hyperchromic areas suspected of ochronosis. Besides the macular lesion, the pinpoint papules of the first, second, and

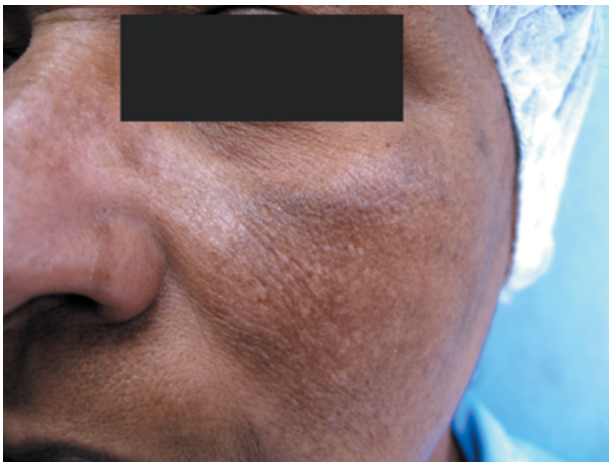


Figure 2 Brown macules, with confetti-like depigmentation on the cheek. Also with darker gray-brown areas, with caviar-like pinpoint papules in the zygomatic region

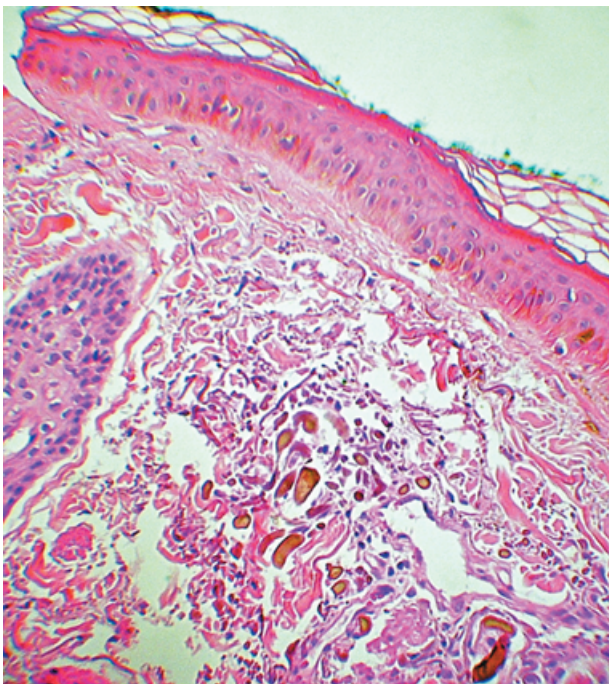


Figure 3 Histopathology of ochronosis lesion, showing normal epidermis, mild pigment incontinence, solar elastosis and brownish-yellow (ochre) "banana shaped" fibers in the papillary dermis. H&E stain $\times 40$

fourth patients were also biopsied. On histopathologic exam, normal epidermis, pigment incontinence in the papillary dermis, solar elastosis, and brownish-yellow (ochre) 'banana-shaped' fibers were found (Fig. 3). There was no variation in the findings, independent of the type of lesion biopsied (macule or pinpoint papule).

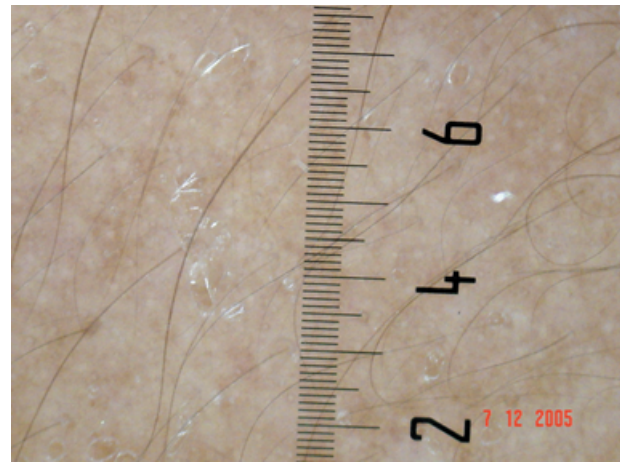


Figure 4 Dermoscopy of melasma lesion ($\times 10$). Showing accentuation of the normal pseudo-rete of the facial skin

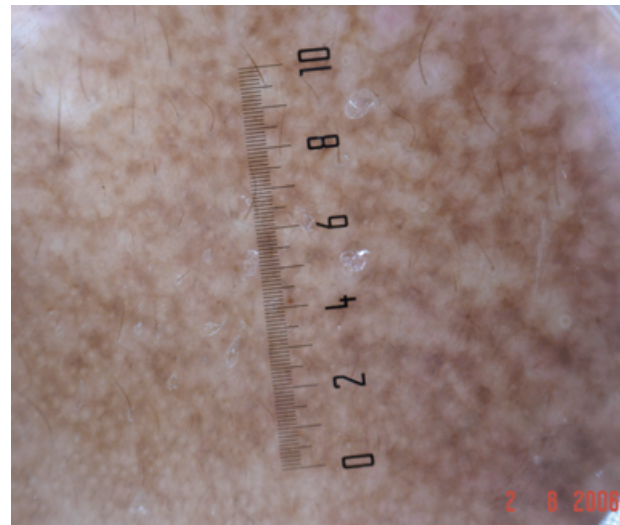


Figure 5 Dermoscopy ($\times 10$). On the left side of the picture (melasma), with accentuation of the normal pseudo-rete of facial skin. On the right side (ochronosis), presenting blue-gray amorphous areas with obliteration of some follicular openings

Patients one and four were subjected to dermoscopy. There was no characteristic pigmentation on the normal skin. In the areas with melasma without ochronosis, an accentuation of the normal pseudo-rete of the facial skin was observed (Figs 4 and 5). In the areas with ochronosis, besides the previous observation, blue-gray amorphous areas obliterating some follicular openings were observed (Figs 5 and 6).

Instituted treatments varied. The first patient was treated with retinoic acid gel 0.05%, azelaic acid cream 20%, and kojic acid cream (Melani D®, La Roche-Posay), with partial improvement of the ochronosis. The second patient abandoned the medical follow-up and the third was subjected to

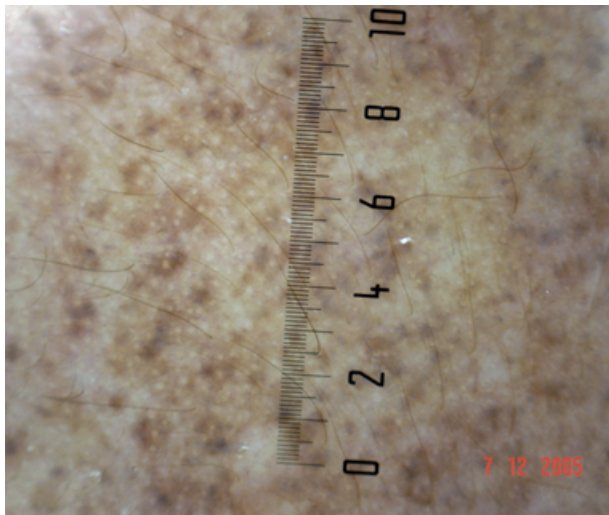


Figure 6 Dermoscopy of ochronosis lesion ($\times 10$). Densely blue-gray structures obliterating some follicular openings

a test with the Nd-Yag laser Q-switched without improvement. Retinoic acid 0.05% and 20% azelaic acid were prescribed for the fourth patient. None of the therapeutic modalities achieved satisfactory results.

Discussion

The four patients have high phototypes – IV and V – similar to the cases of exogenous ochronosis described in the literature. Melasma, the condition for which hydroquinone is used, is also more common in high phototypes. This might explain why exogenous ochronosis is found mostly in these patients.

With respect to the concentrations of hydroquinone applied, the first, second, and fourth patients used relatively low concentrations, but for a long time. The third used higher concentrations in recent years, noticing intensified darkening of the skin after increasing the concentration of the medicine. Thus, we confirm that exogenous ochronosis can occur after use of different concentrations of hydroquinone, prolonged use being the principle factor.

The four patients did not use other drugs related to exogenous ochronosis and no one presented with signs of endogenous ochronosis, i.e., arthralgia, altered urine color, hyperpigmentation of the sclerae, axillae, genitals, or skin over the joints. Neither thickening of the pinnae nor dark cerumen was observed. For the diagnosis of exogenous ochronosis, physicians should, at least clinically, exclude the possibility of endogenous ochronosis.

The color of the patients' lesions corresponds to that described in the literature. In cases 1, 3, and 4, the macules were gray-brown and in case 2, predominantly blue-black. Cases 1, 2, and 4 presented with caviar-like, hyperchromic, pinpoint papules in the zygomatic regions. The third patient

presented with hyperpigmentation of almost the entire face, with 2–3 mm hyperchromic papules and small round depigmented macules (confetti-like depigmentation). Patients 3 and 4 presented with two adverse effects of hydroquinone: exogenous ochronosis and confetti-like depigmentation.

All four cases corresponded with the stage 2 classification for exogenous ochronosis, established by Dogliotte.

The histopathologic exam of the four cases revealed solar elastosis and brownish-yellow (ochre), 'banana-shaped' fibers in the papillary dermis, characteristic of exogenous ochronosis. The four patients did not demonstrate colloid milium or granulomas. There was not a significant difference among the histopathologic exams of the four patients, even though the third patient presented with a more intense clinical picture. Differing from Findlay's⁹ and Jacyk's³⁵ descriptions, we did not find a correlation between the caviar-like pinpoint papules of patients 1, 2, and 4, and the histopathologic presence of colloid milium.

Dermoscopy of patients 1 and 4 showed obvious differences between normal skin, that with melasma, and that with ochronosis. In the literature there is little information about the dermoscopy of melasma. Stolz³⁶ described blue-gray, granular, annular structures around the follicles. However, dermoscopy of melasma involved skin of patients 1 and 4, revealed just accentuation of the normal pseudo-rete of the face. We did not find reports in the literature of dermoscopic examination of ochronosis. In the skin with ochronosis of patients 1 and 4, we observed bluish-gray amorphous areas obliterating the follicular structures rather than surrounding them, as Stolz described for melasma. Of interest, the color of the ochronotic pigment observed clinically and by dermoscopy was blue-gray, not ochre as in the histopathology. The blue color is due to the depth at which the pigment is located (Tyndall effect³⁷).

Concerning the therapy, only the first patient had a partial response, probably from the effect of retinoic acid on the ochronosis and the azelaic and kojic acid on the underlying melasma.

Conclusion

Dermatologists should be prepared to differentiate melasma from exogenous ochronosis induced by topical use of hydroquinone, employed to treat the first condition. An early diagnosis necessitates immediate discontinuation of hydroquinone, rather than increasing the concentration in attempt to clear the dermatosis.

The prescription of hydroquinone for any patient should be accompanied by orientation to the possible side-effects, including information that the drug should be used for a limited period.

There was no reference to the use of dermoscopy on exogenous ochronosis in the researched literature. The

dermoscopic exam of the first and fourth patients revealed differences between the healthy skin, that affected by melasma and that of ochronosis. Dermoscopy might become a valuable complementary exam when approaching patients with exogenous ochronosis.

References

- 1 Virchow R. Ein Fall von allgemeiner ochronose der knorpel aud knorpelähnlichen theile. *Virchows Arch (Pathol Anat)* 1866; 37.
- 2 Fisher AA. Exogenous ochronosis from hydroquinone bleaching cream. *Cutis* 1998; 62: 11–12.
- 3 La Du BN. Alkaptonuria. In: Scriver CR, Beaudet A, Sly W, et al. eds. *The Metabolic and Molecular Bases of Inherited Disease*, 7th edn. New York: McGraw-Hill, 2001, p. 1371.
- 4 Van Offel JF, DeClerck LS, Francx LM, et al. The clinical manifestations of ochronosis: a review. *Acta Clin Belg* 1995; 50: 358–362.
- 5 Goldsmith LA. Cutaneous changes in errors of amino acid metabolism: alkaptonuria. In: Fitzpatrick, TB, Eisen, AZ, Wolff, K, et al. eds. *Dermatology in General Medicine*, Chapter 48. New York: McGraw-Hill, 1993, pp. 1841–1845.
- 6 Beddard AP, Plumtre CM. A further note on ochronosis associated with carboluria. *Q S Med* 1912; 5: 505–507.
- 7 Berry JL, Peat S. Ochrosonis: report of a case with carboluria. *Lancet* 1931; 2: 124–126.
- 8 Brogren N. Case of exogenetic ochronosis from carbolic acid compresses. *Acta Derm Venereol (Stockholm)* 1952; 32: 258–260.
- 9 Findlay GH, Morrison JG, Simson IW. Exogenous ochronosis and pigmented colloid milium from hydroquinone bleaching creams. *Br J Dermatol* 1975; 93: 613–622.
- 10 Sugar HS, Waddell WW. Ochrosonis-like pigmentation associated with the use of atabrine. *Ill Med J* 1946; 89: 234–239.
- 11 Ludwig GD, Toole JF, Wood JC. Ochrosonis from quinacrine (atabrine). *Ann Intern Med* 1963; 59: 378–384.
- 12 Tuffanelli D, Abraham RK, Dubois EI. Pigmentation from antimalarial therapy. Its possible relationship to the ocular lesions. *Arch Dermatol* 1963; 88: 419–426.
- 13 Egorin MJ, Trump DL, Wainwright CW. Quinacrine ochrosonis and rheumatoid arthritis. *JAMA* 1976; 236: 385–386.
- 14 Cullison D, Abele DC, O'Quinn JL. Localized exogenous ochrosonis. *J Am Acad Dermatol* 1983 June; 8: 882–889.
- 15 Diven DG, Smith EB, Pupo RA, et al. Hydroquinone-induced localized exogenous ochrosonis treated with dermabrasion and CO₂ laser. *J Dermatol Surg Oncol* 1990; 16: 1018–1022.
- 16 Fitzpatrick TB. Soleil et peau. *J Med Esthet* 1975; 2: 33.
- 17 Hoshaw RA, Zimmerman KG, Menter A. Ochrosonis-like pigmentation from hydroquinone bleaching creams in Americans blacks. *Arch Dermatol* 1985; 121: 105–108.
- 18 Penneys NS. Ochrosonis-like pigmentation from bleaching creams. *Arch Dermatol* 1985; 121: 1239–1240.
- 19 O'Donoghue MN, Lynfield YL, Derbes V. Ochrosonis due to hydroquinone. *J Am Acad Dermatol* 1983; 8: 123.
- 20 Jordaan HF, Van Niekerk DJ. Transepidermal elimination in exogenous ochrosonis. A report of two cases. *Am J Dermatopathol*; 13: 418–424.
- 21 Kramer KE, Lopez A, Stefanato CM, et al. Exogenous ochrosonis. *J Am Acad Dermatol* 2000; 42 (5 Part 2): 869–871.
- 22 Bellew SG, Alster TS. Treatment of exogenous ochrosonis with a Q-switched alexandrite (755 nm) laser. *Dermatol Surg* 2004; 30 (4 Part 1): 555–558.
- 23 Dogliotte M, Leibowitz M. Granulomatous ochrosonis – a cosmetic-induced skin disorder in blacks. *S Afr Med J* 1979; 56: 757–760.
- 24 Sanchez NP, Pathak MA, Sato S, et al. Melasma: a clinical, light microscopic, ultrastructural, and immunofluorescence study. *J Am Acad Dermatol* 1981; 4: 698–710.
- 25 Kang WH, Yoon KH, Lee ES, et al. Melasma: histopathological characteristics in 56 Korean patients. *Br J Dermatol*; 2002; 146: 228–237.
- 26 Grimes PE, Yamada N, Bhawan J. Light microscopic, immunohistochemical, and ultrastructural alterations in patients with melasma. *Am J Dermatopathol* 2005; 27: 96–101.
- 27 Victor FC, Gelber J, Rao B. Melasma: a review. *J Cutan Med Surg* 2004; 8: 97–102.
- 28 Connor T, Braunstein B. Hyperpigmentation following the use of bleaching creams. Localized exogenous ochrosonis. *Arch Dermatol* 1987; 123: 105–6, 108.
- 29 Howard K, Furner B. Exogenous ochrosonis in a Mexican-American woman. *Cutis* 1990; 45: 180–182.
- 30 Schutz E, Summers B, Summers R. Inappropriate treatment of cosmetic ochrosonis with hydroquinone. *S Afr Med J* 1988; 73: 59–60.
- 31 Snider RL, Thiers BH. Exogenous ochrosonis. *J Am Acad Dermatol* 1993; 28: 662–664.
- 32 Lang PG. Probable coexisting exogenous ochrosonis and mercurial pigmentation managed by dermabrasion. *J Am Acad Dermatol* 1988; 19: 942–946.
- 33 Taylor CR, Gange RW, Dover JS et al. Treatment of tattoos by Q-switched ruby laser: a dose-response study. *Arch Dermatol* 1990; 126: 893–899.
- 34 Hruza GJ, Dover JS, Flotte TJ et al. Q-switched ruby laser irradiation of normal human skin. *Arch Dermatol* 1991; 127: 1799–1805.
- 35 Jacyk WK. Annular granulomatous lesions in exogenous ochrosonis are manifestation of sarcoidosis. *Am J Dermatopathol* 1995; 17: 18–22.
- 36 Stolz W. *Color Atlas of Dermoscopy*, 2nd edn. Berlin: Blackwell Wissenschafts-Verlag G 2002, pp. 121–131.
- 37 Jeghers H. Pigmentation of the skin. *N Engl J Med* 1944; 231: 88–100.